



## Full Mouth Rehabilitation of the Patient with Severely Worn Dentition- A Case Report

**Swaroopkumar M. Magar**

*Reader, Department of Prosthodontics; Saraswati Dhanwantri Dental College & Post Graduate Research Institute, Parbhani, Maharashtra, India.*

### Case Report

#### **Address for Correspondence Author**

**Dr. Swaroopkumar M. Magar;** Department of Prosthodontics; Saraswati Dhanwantri Dental College & Post Graduate Research Institute, Parbhani, Maharashtra, India.

**E-mail:** [drmagar@rediffmail.com](mailto:drmagar@rediffmail.com)

**Crossref doi:** <https://doi.org/10.36437/ijdrd.2021.3.1.M>

### **ABSTRACT**

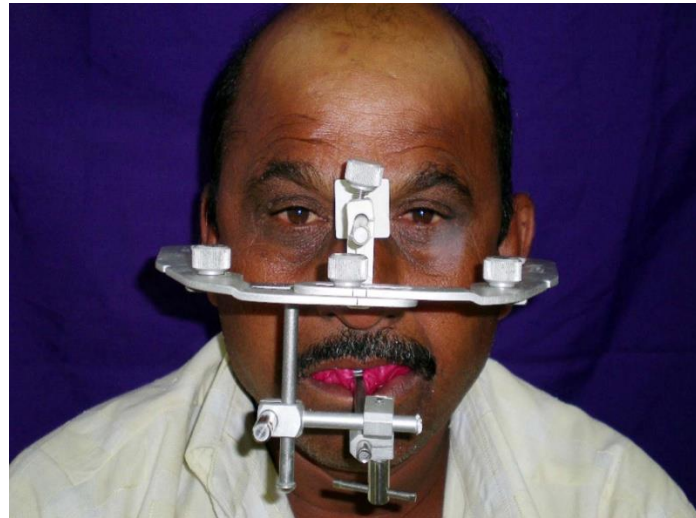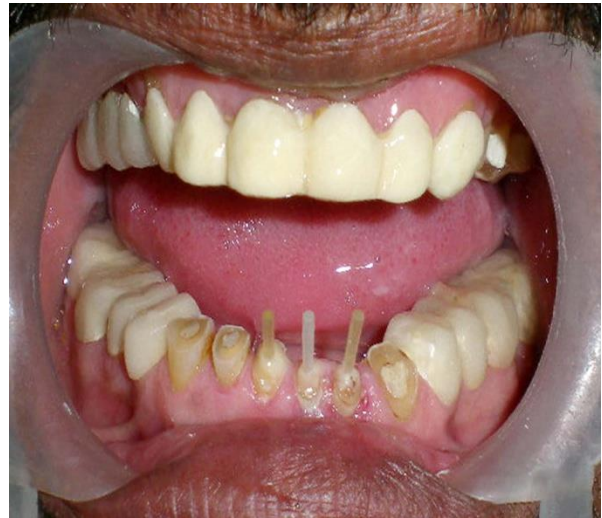
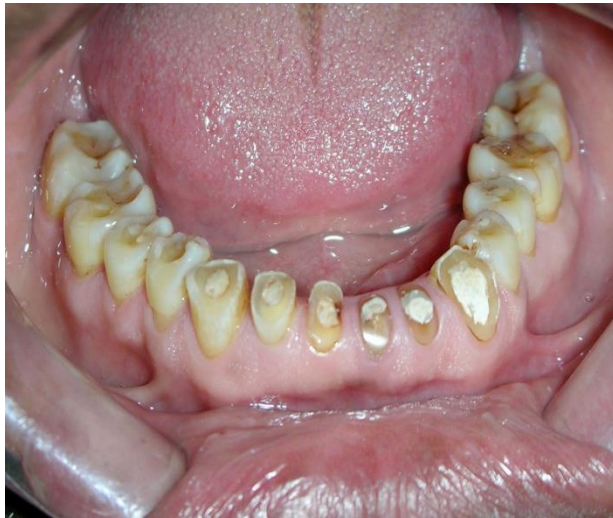The severe wear of anterior teeth facilitates the loss of anterior guidance, which in turn protects posterior teeth from wearing. The loss of the normal occlusal plane and the reduction of vertical dimension occur due to the collapse of posterior teeth. Full mouth rehabilitation allows us to restore severely attrited teeth due to decreased vertical dimension.

**Keywords:** Full Mouth Rehabilitation, Tooth Wear, Vertical Dimension of Occlusion, Occlusal Overly Splint.

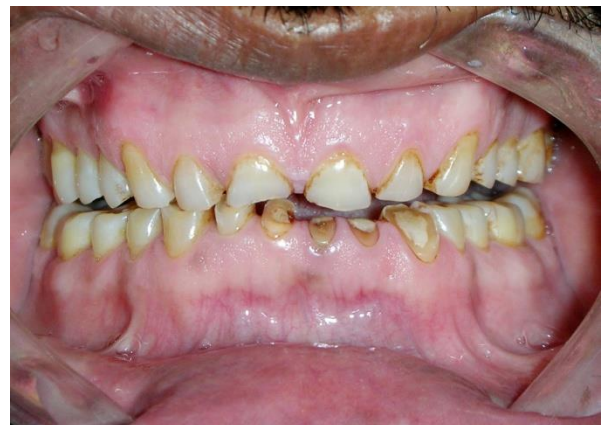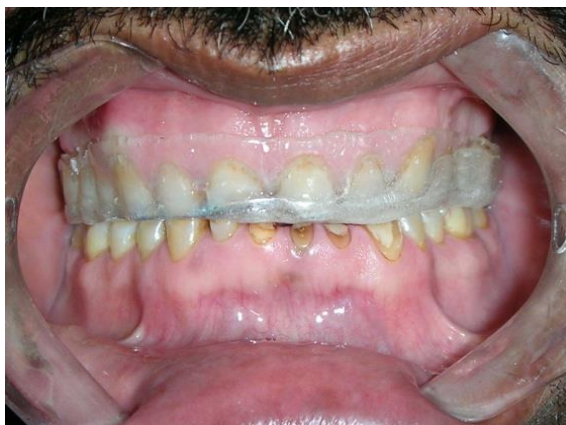### **Introduction**

Attrition is defined as loss of tooth structure by tooth – to –tooth friction without any intervening substance. Occlusal and incisal attrition may occur due to deglutition and if severe bruxism and clenching habits are present. Clinically, attrition is recognized as an occlusal facet in posterior teeth and shiny tooth surfaces.<sup>1,2</sup> Severe attrition may lead to pulpal pathologies<sup>3</sup> disturbed occlusion and esthetics. Full mouth rehabilitation helps us to regain the natural form, function, and esthetics of the tooth by analyzing the mechanical and biological harmony of the tooth, muscle, and jaw.

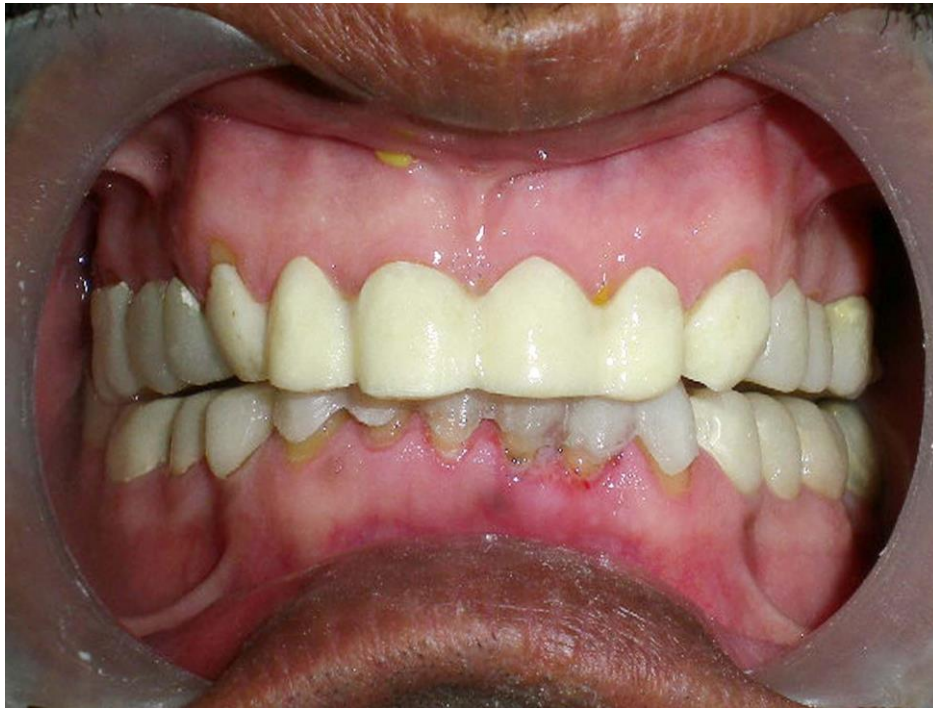**Case report:** A 49 years, male patient reported to the clinic with a chief complaint of pain in lower anterior teeth and severely worn out teeth, and hampered masticatory function. No significant systemic health issue was reported. The patient had a habit of peeling tough wire coating with the help of his teeth as he was an electrician by profession. Intraoral examination revealed severely attrited anterior teeth in upper and lower arches and presences of occlusal facets in posterior teeth in upper and lower arches. The patient was explained about the procedure in detail and his consent was obtained. On proper planning, root canal treatment was carried out from mandibular left canine to mandibular right canine followed by post and core procedure with mandibular right central incisor to mandibular left lateral incisor as severe wear out extending up to gingival level was seen with mandibular right central incisor to mandibular left lateral incisor. To restore vertical height, the vertical dimension of occlusion was recorded using a facebow and was transferred on a semi-adjustable articulator.



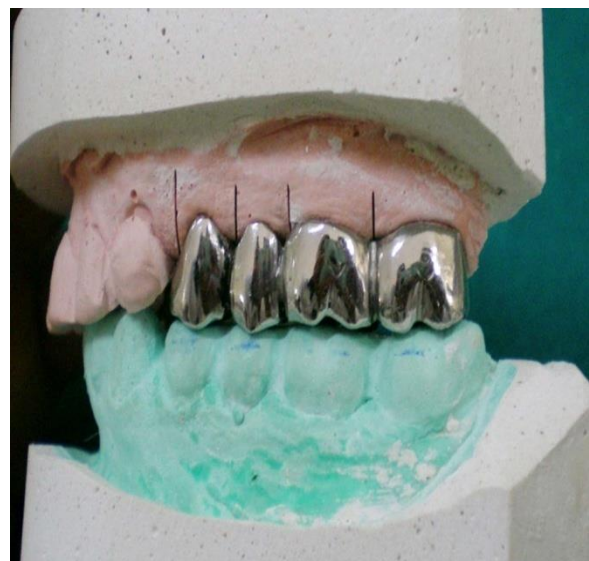
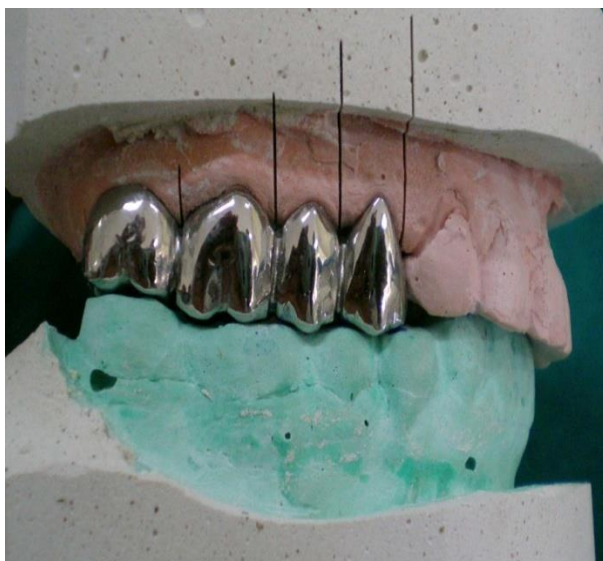With the help of Biostar, increased vertical height was developed. Occlusal overlay splint was delivered and was monitored for one month to evaluate the patient's adaptation to the new vertical dimension of occlusion.

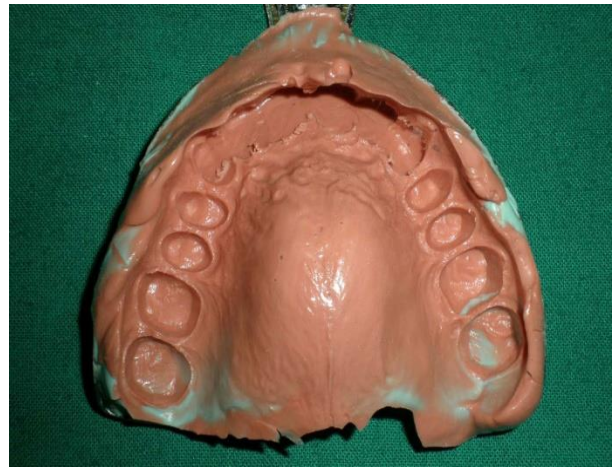
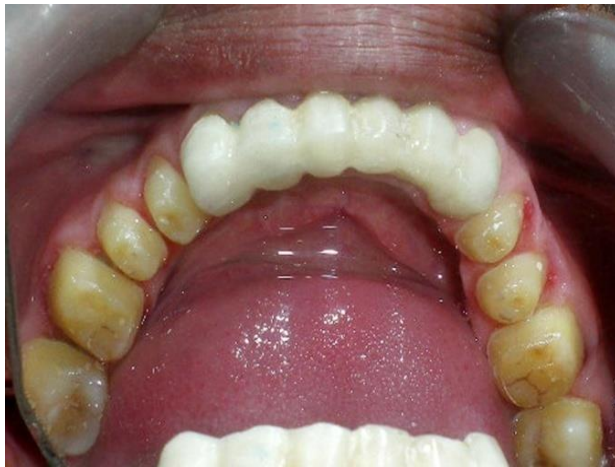

On this increased vertical dimension of occlusion, after 4 weeks provisional restorations were fabricated in the upper and lower arch.

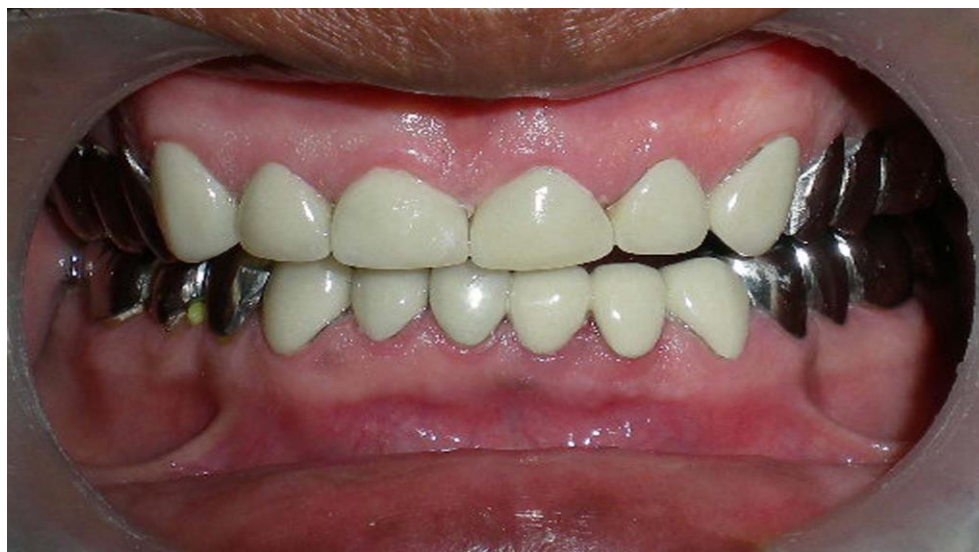
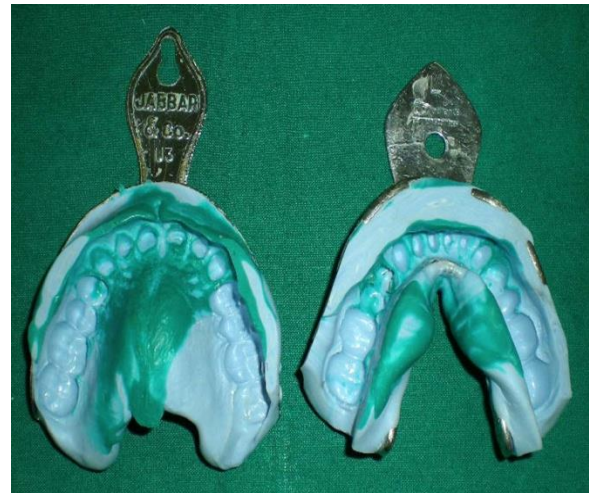
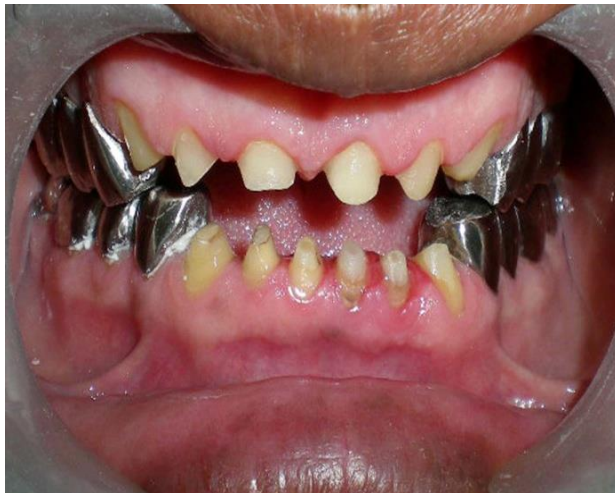The patient was recalled after 2 months i.e 5-6 weeks and his posterior provisional restorations were removed. Definitive tooth preparation was done with upper and lower posterior teeth and their rubber base impression was made. Full metal crowns were fabricated upper and lower posterior teeth which were cemented within a week. Occlusal height was adjusted accordingly in such a way that occlusal rehabilitation was achieved successfully.





Later on, upper and lower anterior provisional restorations were removed and definitive cutting was carried out and their rubber base impressions were made. Porcelain fused metal crowns were fabricated which were cemented within a week.





**Discussion:** Full mouth rehabilitation should reestablish a state of functional and biological efficiency where teeth and their periodontal structures, the muscles of mastication and temporomandibular joint mechanisms all function together in synchronous harmony.<sup>4</sup>

Various classifications<sup>5,6</sup> have been proposed to classify patients requiring full mouth rehabilitations, however, the classification most widely adopted is the one given by Turner and Missirlian.<sup>7</sup>

According to them, patients with occlusal wear can be classified as:

- Category 1:- Excessive wear with loss of vertical dimension of occlusion.
- Category 2:- Excessive wear without loss of vertical dimension of occlusion but with space available.
- Category 3:- Excessive wear without loss of vertical dimension of occlusion but with limited space.

In this case, the patient was monitored for one month to evaluate his adaptation to a removable occlusal overlay. Also, the patient's adaptation to provisional restoration was evaluated for two months. No discomfort, wear and muscle fatigue was observed during this period.

Depending on the patient's situation and adaptation, ability, an interim period can be modified. Careful evaluation and monitoring can shorten the treatment duration.

**Conclusion:** Full mouth rehabilitation at increased vertical dimension is challenging especially when esthetics, function, and adaptation is the main concern. A treatment plan was executed in harmony with the clinical situation. In this case, simplified clinical procedures helped to yield better results and psychological satisfaction and esthetically helped in gaining confidence in socializing with the public.

## References

1. Zeighami S, Siadat H, Nikzad S. Full mouth reconstruction of bruxer with severely worn dentition: A Clinical report case Rep Dent 2015; doi: <https://doi.org/10.1155/2015/531618>
2. Laudenbach JM, Simon Z, Common dental and periodontal diseases: evaluation and management. Med Clin North Am 2014;98:1239-60 doi: <https://doi.org/10.1016/j.mcna.2014.08.002>
3. Grippo JO, Simring m, Schreiner S. Attrition, abrasion, corrosion and abfraction revisited: A new perspective on tooth surface lesion. JAM dent Assoc 2004; 135:1109-18. doi: <https://doi.org/10.14219/jada.archive.2004.0369>
4. Kazis H, kazis AJ. Complete mouth rehabilitation through fixed partial denture prosthodontics. J Prosthet dent.1960; 10:296-303. [https://doi.org/10.1016/0022-3913\(60\)90057-3](https://doi.org/10.1016/0022-3913(60)90057-3)
5. Jones SSM. The principles of obtaining occlusion in occlusal rehabilitation. J Prosthet Dent. 1963; 13:706-713.
6. Brecker SC. Clinical procedures in occlusal rehabilitation. Philadelphia: W.B. Saunders Co; 1958. <https://catalog.hathitrust.org/Record/001571945>
7. Turner KA, Missirlian DM. Restoration of the extremely worn dentition. J Prosthet Dent. 1984; 52:467-474. doi: [https://doi.org/10.1016/0022-3913\(84\)90326-3](https://doi.org/10.1016/0022-3913(84)90326-3)

**How to cite this Article:** Swaroopkumar M. Magar; *Full Mouth Rehabilitation of the Patient with Severely Worn Dentition- A Case Report*; Int. J. Drug Res. Dental Sci., 2021; 3(1): 93-97,

doi: <https://doi.org/10.36437/ijdrd.2021.3.1.M>

**Source of Support:** Nil, **Conflict of Interest:** Nil.

**Received:** 12-1-2021 **Revised:** 12-3-2021 **Accepted:** 15-3-2021